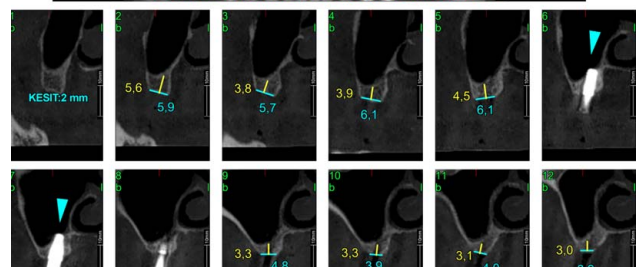
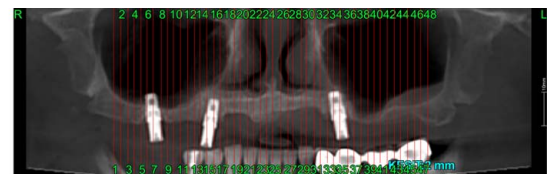


Onur Şahin, DDS, PhD



From the Department of Oral and Maxillofacial Surgery, Faculty of Dentistry, İzmir Katip Çelebi University, İzmir, Türkiye.
Received September 25, 2023.
Accepted for publication October 19, 2023.
Address correspondence and reprint requests to Onur Şahin, DDS, PhD, Department of Oral and Maxillofacial Surgery, Faculty of Dentistry, İzmir Katip Çelebi University, Aydınlıkevler Mah. 6782 Sok. No: 48 35640 Çiğli, İzmir, Türkiye; E-mail: onursahin43@hotmail.com
The authors report no conflicts of interest.
Copyright © 2023 by Mutaz B. Habal, MD
ISSN: 1049-2275
DOI: 10.1097/SCS.00000000000009896

FIGURE 1. Preop CBCT images of the patient. CBCT indicate cone beam computed tomography.